

Patellofemoral pain

Kay M Crossley,¹ Michael J Callaghan,² Robbart van Linschoten³

¹School of Allied Health, La Trobe University, Melbourne, Vic3086, Australia;

²Centre for Musculoskeletal Research, Institute for Inflammation and Repair, University of Manchester, UK;

³Aspetar, Qatar Orthopaedic and Sports Medicine Hospital, Doha, Qatar

Correspondence to

K M Crossley k.crossley@latrobe.edu.au

ABSTRACT

Patellofemoral pain refers to pain behind or around the patella (also known as patellofemoral pain syndrome, anterior knee pain, runner's knee, and, formerly, chondromalacia patellae). Patellofemoral pain is common, accounting for 11-17% of all knee pain presentations to general practice.^{1 2} While it typically occurs in physically active people aged <40 years, it also affects people of all activity levels and ages.^{1 2} Patellofemoral pain can be diagnosed in the clinic, and evidence based treatments can reduce pain and improve function, allowing patients to maintain a physically active lifestyle.

HOW DO PATIENTS PRESENT?

Patients commonly describe a gradual onset of anterior knee pain, usually unrelated to trauma, but associated with an increased frequency or duration of patellofemoral loaded activities (squatting, climbing stairs, hiking, running). Pain is rarely present when the patellofemoral joint is not loaded (during sleeping, standing, resting). Importantly, although the dominant symptom is pain, patients often also describe patellofemoral crepitus, knee stiffness, difficulty with activities of daily living, restricted physical activity, and poor quality of life. Patellofemoral pain symptoms can persist for up to 20 years.⁷

Patients may stop or curtail physical activity as a result of pain. This may lead to weight gain, further increasing patellofemoral joint loading and pain, setting off a vicious cycle that may discourage patients from further physical activity.

Patellofemoral pain may also present after patellar dislocation or subluxation. Less typically, patellofemoral pain can follow acute trauma (such as a direct blow to the patella) or other knee injury, such as a meniscal tear or ruptured anterior cruciate ligament.

Patellofemoral pain typically affects younger adults but is also problematic for adolescents and older adults. For adolescents, this is especially evident during periods of rapid growth.⁶ In older patients, degenerative changes in the patellofemoral joint may be present, accompanied by joint stiffness and crepitus: in community based studies, radiographic signs of osteoarthritis were evident in approximately 70% of people with patellofemoral pain aged >40 years.^{8 9}

HOW IS IT DIAGNOSED?

Patellofemoral pain is a clinical diagnosis, primarily based on the symptoms of anterior knee pain aggravated by patellofemoral loaded activities, such

as stair climbing, squatting, running, hiking, and rising from sitting.

There is no definitive clinical test to diagnose patellofemoral pain.¹⁰ The best available test is anterior knee pain elicited during a squatting manoeuvre: patellofemoral pain is evident in 80% of people who are positive on this test.¹⁰ Several other tests proposed for patellofemoral pain have limited evidence supporting their use: patellofemoral pain is evident in 71-75% of people with tenderness on palpation of the patellar edges,¹⁰ but patellar grinding and apprehension tests have low sensitivity and limited diagnostic accuracy for patellofemoral pain.¹⁰ Physical examination usually reveals a full range of knee motion and no effusion.

From a systematic review, other features associated with patellofemoral pain include patellofemoral morphology (shallower or wider femoral trochlea, laterally tilted patella), altered lower limb movement patterns (more hip adduction and internal rotation), and muscle weaknesses (weaker quadriceps, hip abduction and hip external rotation, delayed onset of the medial compared with lateral quadriceps).³ However, these features are difficult to measure in routine general practice, requiring magnetic resonance imaging (MRI), dynamometers (to measure strength), or motion analysis systems.

Patellofemoral pain that is accompanied by radiographic evidence of osteoarthritis in the patellofemoral joint (that is, osteophytes or joint space narrowing) is an indicator of patellofemoral osteoarthritis. This may be isolated or combined with tibiofemoral osteoarthritis.

The bottom line

- ▶ Patellofemoral pain commonly presents as gradual onset of knee pain (behind or around the patella) associated with patellofemoral loaded activities (squatting, climbing stairs, hiking, running)
- ▶ Imaging is rarely indicated
- ▶ Conservative therapies (especially physiotherapist-led exercise, targeted exercises based on the clinical findings, foot orthoses) are effective
- ▶ Accurate diagnosis and explanation of the condition and rationale for the rehabilitation programme, with some indication of timeline for prognosis, improves the likelihood of a successful outcome



To cite: Crossley KM, Callaghan MJ, Linschoten R van. *Br J Sports Med* 2016;**50**:247-250.

Sources and selection criteria

We undertook a literature review from recent systematic reviews,^{3–5} updated to June 2104. We used the search terms (patell* OR femoropatell* OR femoro-patell* OR retropatell*) AND (pain OR syndrome OR dysfunction) combined with (risk factor OR association OR relative risk) and (rehabilitation OR physi* therapy OR exercise therapy OR ortho* OR electrotherapy OR tap* OR strengthening OR brace OR ortho*). We selected papers that represented the best available evidence, systematic reviews, and randomised controlled trials where possible. The published consensus paper from the 2014 international patellofemoral research retreat⁶ reviewed the best available evidence on patellofemoral pain and was used when systematic reviews were not available or to confirm systematic review findings. We also included our own personal clinical and research experiences in patellofemoral pain, especially for the sections with limited evidence (such as diagnosis, imaging, and options for failed management).

DIFFERENTIAL DIAGNOSIS

Undertake a thorough knee and hip examination (especially in children and adolescents), to exclude other sources or causes of anterior knee pain symptoms (see videos at www.youtube.com/playlist?list=PLAD99E958AC0F43B1). Localised pain at the inferior patellar pole suggests patellar tendinopathy, seen in adults involved in jumping sports or known as Sinding Larssen disease in children. Localised tenderness and swelling around the tibial tuberosity in adolescents points to Osgood Schlatter disease (overuse syndrome with patellar tendon traction).

A history of acute knee trauma and swelling (with or without knee locking) usually suggest ligament sprains or ruptures, patellar dislocations, or acute meniscal tears. Sensations of the patella “moving,” “slipping,” or “popping out” suggest patellar subluxation or instability, especially during rotational activities (such as twisting or changing direction), or, in a person with hypermobility, shallower femoral trochlea or a small, high riding patella.

Prolonged morning stiffness >30 minutes, involvement of multiple joints or tendons, and joint swelling may be a presentation of systemic joint disease requiring referral to a rheumatologist.

WHAT RED FLAGS WARRANT SPECIALIST REFERRAL?

All patients—Fever, significant knee swelling, increased temperature over the knee joint, or night pain may point to septic arthritis, septic bursitis, osteomyelitis, or a tumour.

Children and adolescents—A limp, leg length discrepancy, or painful, reduced hip range of motion (see videos cited above) may indicate Perthes disease (disruption of the blood supply to the hip, which may lead to avascular necrosis) or a slipped femoral capital epiphysis. Mild effusion (see videos) and a locking sensation in children’s knees could indicate osteochondritis dissecans (degeneration or necrosis of small areas of bone and cartilage within the joint).

IS IMAGING WARRANTED?

Imaging is usually not required to diagnose patellofemoral pain, but it may help to identify potential sources of nociception (such as signs of early joint disease, subchondral bone lesions, and synovium or fat pad inflammation).

Imaging may also be useful to identify alternative causes of knee pain:

- ▶ In people with a history of patellar dislocation or repeated subluxations, direct trauma, or with persistent swelling and pain (when osteochondral lesion of the knee is suspected), radiography (including a skyline and tunnel view) may identify bony causes of pain such as avulsions, fracture, or osteochondral lesions.
- ▶ In patients with inferior patellar pain associated with activities such as jumping and landing, ultrasound scans can reveal patellar tendinopathy.
- ▶ In people aged >40 years with persistent pain, radiography (including a skyline view) can reveal signs of osteoarthritis.

There is no role for MRI to diagnose patellofemoral pain because of limited diagnostic accuracy for low grade cartilage lesions,¹¹ poor association between articular cartilage damage and patellofemoral pain symptoms,¹¹ and high prevalence of cartilage lesions (14%) in athletic asymptomatic people.¹² There are also few studies on the clinical significance of knee MRI findings in adolescents with patellofemoral symptoms.

HOW IS IT MANAGED?

Referral for physiotherapy (for supervised exercise and quadriceps or hip exercises) or shoe orthotics is an important component of management.⁵ As these options are similarly effective, choosing between different options should be a shared decision, incorporating patient preference, values, past experiences, and clinical findings.¹³ Physiotherapist-led exercise is shown to be better than no treatment, but the best results are obtained with a combination of targeted exercises based on the clinical findings and augmented, where appropriate, by foot orthotics. Benefits can be expected 6–12 weeks after starting physiotherapy.

Referral should be made as early as possible, since greater severity and longer duration of patellofemoral pain predicts poorer prognosis.¹⁴ However, there is currently insufficient evidence to predict which patients are most likely to respond to treatment.⁴ Weight management may also be an important consideration.

Best results and patient adherence follow an accurate diagnosis, with a clear explanation of the condition and the rationale for the coordinated physiotherapy programme, with some indication of prognosis (see box). A simplified exercise intervention that is part of a patient’s regular routine may improve long term adherence and speed recovery.⁶

PHYSIOTHERAPY

In a high quality randomised controlled trial, physiotherapist-delivered exercise therapy with quadriceps and hip strengthening exercises over six weeks significantly reduced pain and improved function and recovery rates (number needed to treat (NNT) 3.6 (95% confidence interval 2.3 to 8)) compared with watchful waiting.¹⁵

In a systematic review, multimodal physiotherapy (strengthening, movement retraining, patellar taping, and mobilisation) led to statistically and clinically significant improvements in pain compared with sham interventions.⁵ Patellar taping (generally applied over and around the patella to move it medially, fig 2) and mobilisation (medial, lateral inferior, and superior glides) provide pain relief and can enhance the effectiveness of the rehabilitation programme. However, the mechanism underpinning this pain relief is not known, and a recent Cochrane review showed that patellar tape is ineffective as a stand-alone treatment.¹⁶

Advice to patients regarding management

- ▶ Patellofemoral pain is a common knee condition with a gradual onset. Importantly, how you move (hip, knee, foot movements), the alignment of your kneecap in the groove of the thigh bone, and the strength of your muscles will affect the load on your kneecap and can result in pain (figure 1).
- ▶ Conservative therapies (especially physiotherapist-led exercise, targeted exercises based on the clinical findings, and foot orthotics) can address some of these factors (altered hip, knee, or foot movements, kneecap alignment, muscle strength) and have been shown to reduce pain and improve physical function.
- ▶ Most people have noticeable improvement 6–12 weeks after starting physiotherapy. However, people who have had pain for longer may need additional time to respond.
- ▶ Patients who adhere to the instructions (that is, complete their exercises) have a better response to treatment.
- ▶ If you don't have noticeable improvement with the first therapy that you try (such as supervised exercise), you can substitute or supplement with additional therapies (such as foot orthotics, patellar taping (figure 2), or kneecap mobilisation)
- ▶ A coordinated approach between you, your doctor, and other healthcare providers is essential to improve the likelihood of a successful outcome.
- ▶ Imaging (radiographs, MRI scans) are rarely needed.

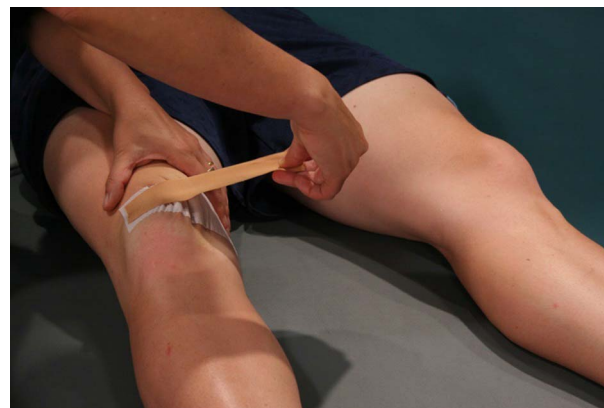

Figure 2 Patellar taping is a useful addition to physiotherapy-led exercise, although ineffective alone.⁵ 16 Tape is applied to the lateral aspect of the patella. Skin medial to the patella is brought towards the patella, and the tape attached onto the medial knee region. Reproduced with permission from Brukner and Khan's *Clinical Sports Medicine*, McGraw Hill

FOOT ORTHOTICS

In a high quality randomised controlled trial, in-shoe foot orthotics ("off the shelf" or prefabricated insoles with a medial arch) resulted in greater improvement than flat (sham) orthotics (NNT 4 (99% confidence interval 2 to 51)), possibly by changing foot and lower limb alignment or muscle activation patterns.

OTHER PHYSICAL AGENTS

Traditional physical agents such as ice or cold, ultrasound, phonophoresis, iontophoresis, neuromuscular electrical stimulation, electrical stimulation for pain control, electromyographic biofeedback, and laser do not reduce pain or improve function in patients with patellofemoral pain, as indicated in a recent systematic review.¹⁷ There is little justification for these modalities, used alone, to treat patellofemoral pain.

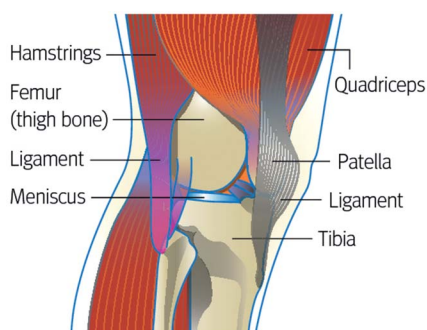


Figure 1 Lateral view of knee. Patellofemoral pain may be associated with patellar malalignment and quadriceps weakness³

ADOLESCENTS

A high quality, cluster randomised controlled trial (121 adolescents) suggests that adolescents who receive patient education and exercise therapy and who adhere to the latter are more likely to recover at 12 months (NNT of 11) and 24 months (NNT of 5), compared with those receiving patient education alone.¹⁸ However, more studies are needed to confirm these findings.

PATELLOFEMORAL OSTEOARTHRITIS

People with patellofemoral osteoarthritis have similar impairments to those with patellofemoral pain (such as patellar malalignment, quadriceps and hip muscle weakness) and have been shown to benefit from similar interventions. A 12 week programme of exercise, education, manual therapy, and taping resulted in patient perceived improvement (NNT of 3 (95% confidence interval 2 to 5)),¹⁹ and clinically significant improvements in pain and function were observed after six weeks of wearing a sleeve type patellofemoral brace.²⁰

WHAT IF PATIENTS DO NOT RESPOND TO PHYSICAL AND EXERCISE THERAPY?

For some patients, recovery from patellofemoral pain is protracted despite persistence and adherence to the rehabilitation approach.⁶ They may wish to consider adjunctive therapies, such as acupuncture,⁵ non-steroidal anti-inflammatory drugs,²¹ or movement retraining programmes (such as running retraining).⁶ Although there is limited support for their use in the literature, they are regularly recommended by clinicians.

Patients with persistent pain that is non-specific and inconsistent, with a non-mechanical pattern (that is, pain not related to activities that would be expected to load the joint) may be exhibiting signs of central sensitisation or psychosocial impairments. Few studies have investigated these impairments in people with patellofemoral pain.³ Consider referring such patients to a physician or physiotherapist with expertise in pain management.

We lack evidence from randomised controlled trials of the benefit of surgery to reduce patellofemoral pain. Given the invasive nature and risks of surgery, there seems to be no evidence based role for surgery. Persistent swelling or locking, combined with abnormal findings on imaging (such as cartilage lesion), are

Republished research

often considered indications for surgery (such as debridement or microfracture), but few high quality studies have correlated these imaging features with patellofemoral pain.¹¹

How patients were involved in the creation of this article

Two patients with patellofemoral pain were asked to provide feedback on the article, including whether the issues discussed were relevant to them and their condition. As a result of their feedback, we altered the section "How do patients present?" to highlight the presence of associated knee stiffness, difficulty with activities of daily living, restricted physical activity and poor quality of life, and the impact of patellofemoral pain on activity cessation and weight gain.

Competing interests: None declared.

Provenance and peer review: Commissioned; externally peer reviewed.

- 1 Wood L, Muller S, Peat G. The epidemiology of patellofemoral disorders in adulthood: a review of routine general practice morbidity recording. *Prim Health Care Res Dev* 2011;12:157–64.
- 2 Van Middelkoop M, van Linschoten R, Berger MY, et al. Knee complaints seen in general practice: active sport participants versus non-sport participants. *BMC Musculoskelet Disord* 2008;9:36.
- 3 Lankhorst NE, Bierma-Zeinstra SMA, Van Middelkoop M. Factors associated with patellofemoral pain syndrome: a systematic review. *Br J Sports Med* 2013;47:193–206.
- 4 Lack S, Barton C, Vicenzino B, et al. Outcome predictors for conservative patellofemoral pain management: a systematic review and meta-analysis. *Sports Med* 2014;44:1703–16.
- 5 Collins NJ, Bisset LM, Crossley KM, et al. Efficacy of nonsurgical interventions for anterior knee pain: systematic review and meta-analysis of randomised trials. *Sports Med* 2012;42:31–49.
- 6 Witvrouw E, Callaghan MJ, Stefanik JJ, et al. Patellofemoral pain: consensus statement from the 3rd International Patellofemoral Pain Research Retreat held in Vancouver, September 2013. *Br J Sports Med* 2014;48:411–4.
- 7 Thomas MJ, Wood L, Selfe J, et al. Anterior knee pain in younger adults as a precursor to subsequent patellofemoral osteoarthritis: a systematic review. *BMC Musculoskelet Disord* 2010;11:201.
- 8 Hinman RS, Lentzos J, Vicenzino B, et al. Patellofemoral osteoarthritis is common in middle-aged people with chronic patellofemoral pain. *Arthritis Care Res (Hoboken)* 2014;66:1252–7.
- 9 Duncan R, Hay E, Saklatvala J, et al. Prevalence of radiographic osteoarthritis: It all depends on your point of view. *Rheumatology* 2006;45:757–60.
- 10 Nunes GS, Stapaite EL, Kirsten MH, et al. Clinical test for diagnosis of patellofemoral pain syndrome: systematic review with meta-analysis. *Phys Ther Sport* 2013;14:54–9.
- 11 Pihlajamäki HK, Kuikka PI, Leppänen VV, et al. Reliability of clinical findings and magnetic resonance imaging for the diagnosis of chondromalacia patellae. *J Bone Joint Surg Am* 2010;92:927–34.
- 12 Flanigan DC, Harris JD, Trinh TQ, et al. Prevalence of chondral defects in athletes' knees: a systematic review. *Med Sci Sports Exerc* 2010;42:1795–801.
- 13 Hoffmann TC, Montori VM, Del Mar C. The connection between evidence-based medicine and shared decision making. *JAMA* 2014;312:1295–6.
- 14 Collins NJ, Bierma-Zeinstra SMA, Crossley KM, et al. Prognostic factors for patellofemoral pain: a multicentre observational analysis. *Br J Sports Med* 2013;47:227–33.
- 15 Van Linschoten R, Van Middelkoop M, Berger MY, et al. Supervised exercise therapy versus usual care for patellofemoral pain syndrome: an open label randomised controlled trial. *BMJ* 2009;339:1010–3.
- 16 Callaghan MJ, Selfe J. Patellar taping for patellofemoral pain syndrome in adults. *Cochrane Database Syst Rev* 2012;4:CD006717.
- 17 Lake DA, Wofford NH. Effect of therapeutic modalities on patients with patellofemoral pain syndrome: a systematic review. *Sports Health* 2011;3:182–9.
- 18 Rathleff MS, Roos EM, Olesen JL, et al. Exercise during school hours when added to patient education improves outcome for 2 years in adolescent patellofemoral pain: a cluster randomised trial. *Br J Sports Med* 2015;49:406–12.
- 19 Crossley KM, Vicenzino B, Lentzos J, et al. Exercise, education, manual-therapy and taping compared to education for patellofemoral osteoarthritis: a blinded, randomised clinical trial. *Osteoarthritis Cartilage* 2015. doi:10.1016/j.joca.2015.04.024 [epub ahead of print].
- 20 Callaghan MJ, Parkes MJ, Hutchinson CE, et al. A randomised trial of a brace for patellofemoral osteoarthritis targeting knee pain and bone marrow lesions. *Ann Rheum Dis* 2015;74:1164–70.
- 21 Heintjes E, Berger MY, Bierma-Zeinstra SM, et al. Pharmacotherapy for patellofemoral pain syndrome. *Cochrane Database Syst Rev* 2004;3:CD003470.



Patellofemoral pain

Kay M Crossley, Michael J Callaghan and Robbart van Linschoten

Br J Sports Med 2016 50: 247-250

doi: 10.1136/bjsports-2015-h3939rep

Updated information and services can be found at:
<http://bjsm.bmj.com/content/50/4/247>

	<i>These include:</i>
References	This article cites 18 articles, 6 of which you can access for free at: http://bjsm.bmj.com/content/50/4/247#ref-list-1
Email alerting service	Receive free email alerts when new articles cite this article. Sign up in the box at the top right corner of the online article.

Topic Collections	Articles on similar topics can be found in the following collections Patellofemoral pain (52) Degenerative joint disease (239) Musculoskeletal syndromes (431)
--------------------------	---

Notes

To request permissions go to:
<http://group.bmj.com/group/rights-licensing/permissions>

To order reprints go to:
<http://journals.bmj.com/cgi/reprintform>

To subscribe to BMJ go to:
<http://group.bmj.com/subscribe/>